Check for updates

Diagnosis of Hypersensitivity Pneumonitis in Adults, 2020 Clinical Practice Guideline: Summary for Clinicians

Megan A. Koster[1], Carey C. Thomson[1], Bridget F. Collins[2], Alex R. Jenkins[3], Joseph K. Ruminjo[4], and Ganesh Raghu[2]

[1]Division of Pulmonary and Critical Care, Department of Medicine, Mount Auburn Hospital, Harvard Medical School, Cambridge, Massachusetts; [2]Center for Interstitial Lung Diseases, Department of Medicine, University of Washington Medical Center, Seattle, Washington; [3]Division of Respiratory Medicine, University of Nottingham, Nottingham, United Kingdom; and [4]American Thoracic Society, New York, New York

Summary of: Raghu G, Remy-Jardin M, Ryerson CJ, Myers JL, Kreuter M, Vasakova M, et al. Diagnosis of hypersensitivity pneumonitis in adults: an official ATS/JRS/ALAT clinical practice guideline. Am J Respir Crit Care Med 2020;202:e36–e69.

Hypersensitivity pneumonitis (HP) is characterized by inflammatory and/or fibrotic destruction of the lung parenchyma and small airways mediated by an immune response to an inhaled antigen in a susceptible individual (1, 2). Historic categories of acute, subacute, or chronic HP without precise radiographic, histopathologic, and prognostic correlates have made diagnosis and treatment challenging. An *ad hoc*, multidisciplinary committee of international experts from North America, Japan, Latin America, Europe, and Australia, appointed by the American Thoracic Society, Japanese Respiratory Society, and the Asociación Latinoamericana del Tórax, consolidated available evidence informing clinical features of HP, publishing new diagnostic criteria and graded recommendations for the diagnostic approach (2). This summary is intended to provide the practicing clinician with key points from the guideline.

This guideline complements the 2018 American Thoracic Society/European Respiratory Society/Japanese Respiratory Society/Asociación Latinoamericana del Tórax guideline on the diagnosis of idiopathic pulmonary fibrosis (IPF) and focuses on the diagnostic approach to the adult patient with interstitial lung disease (ILD) in whom the history suggests a potential culprit exposure (3). Guidelines have different implications for patients, clinicians, and policymakers (Table 1). Clinicians should always consider unique patient characteristics and preferences when evaluating patients with ILD.

Definition

HP is the culmination of a dysregulated immune response to an inciting inhaled antigen when identified in a sensitized susceptible individual manifesting as inflammation and/or fibrosis of the lung parenchyma and small airways (2). Previously described categories of acute, subacute, and chronic HP are arbitrary and fail to meaningfully inform expectations of prognosis. Conversely, radiographic and histopathologic categorization are strong determinants of prognosis (4, 5). The predominant presence or absence of radiographic or histopathologic fibrosis can be leveraged to define a new classification of nonfibrotic HP (NFHP) purely inflammatory phenotype versus fibrotic HP (FHP) that includes mixed inflammatory plus fibrotic or purely fibrotic phenotypes.

Clinical Manifestations

Symptoms and Prognosis

NFHP and FHP are characterized by symptoms of dyspnea, cough, or, less frequently, constitutional symptoms such as weight loss, chills, low-grade fever, malaise, chest tightness, and wheezing (1). Symptoms can develop acutely over days to weeks or insidiously over months to years. Timing of symptom onset has not been associated with presence or absence of fibrosis. When present, inspiratory squeaks are characteristic findings on auscultation. Patients may stabilize or fully recover (especially in NFHP) upon elimination of the relevant exposure or progress to respiratory failure and death. Factors associated with poor prognosis include patients with FHP (particularly with a usual interstitial pneumonitis [UIP] pattern), cigarette smoking, lower baseline vital capacity (VC), lack of bronchoalveolar lavage (BAL) lymphocytosis, persistent exposure to the inciting agent, and lack of identification of the inciting agent (6, 7).

Epidemiology

HP prevalence varies with regional differences in climate, occupational exposures, and environmental exposures and is highest among older individuals in the fifth and sixth decade of life (8). Patients with FHP are more likely to be older, more unlikely to have an identified inciting agent, and more likely to have lower VC and diffusion capacity than patients with NFHP (9).

(Received in original form September 24, 2020; accepted in final form November 3, 2020)

Correspondence and requests for reprints should be addressed to Megan A. Koster, M.D., Pharm.D., 300 Mount Auburn Street, #419, Cambridge, MA 02138. E-mail: megan.koster@mah.org.

CME will be available for this article at www.atsjournals.org.

Ann Am Thorac Soc Vol 18, No 4, pp 559–566, Apr 2021
Copyright © 2021 by the American Thoracic Society
DOI: 10.1513/AnnalsATS.202009-1195CME
Internet address: www.atsjournals.org

Table 1. Implications of recommendations

	Recommendation ("We Recommend…")	Suggestion* ("We Suggest…")
For patients	The overwhelming majority of individuals in this situation would want the recommended course of action, and only a small minority would not.	The majority of individuals in this situation would want the suggested course of action, but a sizeable minority would not.
For clinicians	The overwhelming majority of individuals should receive the recommended course of action. Adherence to this recommendation according to the guideline could be used as a quality criterion or performance indicator. Formal decision aids are not likely to be needed to help individuals make decisions consistent with their values and preferences.	Different choices will be appropriate for different patients, and you must help each patient arrive at a management decision consistent with her or his values and preferences. Decision aids may be useful to help individuals make decisions consistent with their values and preferences. Clinicians should expect to spend more time with patients when working toward a decision.
For policymakers	The recommendation can be adapted as policy in most situations including for the use as performance indicators.	Policymaking will require substantial debates and involvement of many stakeholders. Policies are also more likely to vary between regions. Performance indicators would have to focus on the fact that adequate deliberation about the management options has taken place.

From the GRADE (Grading of Recommendations, Assessment, and Evaluation) working group. Adapted by permission from Reference 2.
*The meaning of a suggestion is the same as a weak or conditional recommendation in typical GRADE nomenclature.

Pathogenesis

Although the culprit exposure is frequently not identified, HP develops in response to repeated exposure to one or more inciting agents, which may take the form of organic particulates (including microbial, animal, or plant antigens) or inorganic chemicals, pharmaceuticals, and metals. Antigens known to cause HP are listed in the guideline (2). The ensuing immune response includes both humoral (i.e., antigen-specific immunoglobulin [Ig]G antibodies) and cellular (i.e., T-helper cell type 1) components, which result in lymphocyte-predominant and granulomatous inflammation (10). Genetic predisposition is the best-studied host susceptibility factor, including impairments in innate and adaptive immunity, telomere-related mutations, and, in patients with FHP, polymorphisms in MUC5B (mucin 5b) promoter (11–13).

Radiological Features

Volumetric scanning of the chest by high-resolution computed tomograpic (HRCT) imaging with two series of supine images (one at deep inspiration and another after prolonged expiration) is the preferred diagnostic approach for HP. Prone or contrast-enhanced images are not required. The guideline proposes a classification scheme for HRCT patterns associated with NFHP and FHP: *Typical HP*, *Compatible with HP*, and *Indeterminate for HP* (FHP only) (Table 2) (2).

The guideline defines radiologic terms associated with heterogeneous lung attenuation: mosaic attenuation, air trapping, and mosaic perfusion. The newly introduced descriptive term "three-density pattern" refers to inspiratory HRCT images with sharply demarcated regions of three attenuations: normal lung, high-attenuation ground-glass opacity (GGO), and lucent lung (decreased attenuation or decreased vasculature). The guideline strongly discourages the use of the term "headcheese sign," which has been used by some radiologists to describe sharply demarcated regions of three attenuations, and encourages the use of "three-density pattern" for this radiologic feature consistent with HP (2).

Nonfibrotic HP

Essential HRCT features of *Typical NFHP* include diffuse infiltrative parenchymal abnormalities with GGO or mosaic attenuation and at least one abnormality suggesting small airway disease (ill-defined <5 mm centrilobular nodules on inspiratory images or air trapping on expiratory images). In NFHP, mosaic attenuation usually reflects lobules with pneumonitis (high attenuation) adjacent to lobules with normal or decreased attenuation due to bronchiolar obstruction. In the appropriate clinical context, features of uniform or subtle GGO, airspace consolidation, or lung cysts may be considered *Compatible with NFHP*.

Fibrotic HP

FHP is suggested by concomitant fibrosis and bronchiolar obstruction. In *Typical FHP*, lung fibrosis is prominent in mid/lower lung zones or equally distributed with relative basilar sparing without central or peripheral predominance. Evidence of bronchiolar obstruction includes ill-defined centrilobular nodules, GGO, mosaic attenuation, air trapping, and/or the three-density pattern, which is highly specific for FHP (14). HRCT features *Compatible with FHP* include variants in fibrosis pattern (UIP or extensive GGO with superimposed fibrosis) and distribution (upper lobe, peribronchovascular, or subpleural predominance) with corresponding small airway disease. Fibrosis alone (UIP, nonspecific interstitial pneumonitis [NSIP], or organizing pneumonia pattern), without coexistent bronchiolar obstruction, is *Indeterminate for FHP*.

Histopathological Features

Histopathological criteria for diagnosis of NFHP (cellular) and FHP apply to any biopsy technique. Findings suggestive of HP are present in both NFHP and FHP, the latter having the additional component of

Table 2. Chest HRCT features of HP

HRCT Pattern	Typical HP	Compatible with HP	Indeterminate for HP
NFHP pattern			
Description	"Typical HP" pattern is suggestive of a diagnosis of NFHP. It requires *1*) at least one HRCT abnormality indicative of parenchymal infiltration and *2*) at least one HRCT abnormality indicative of small airway disease, both in a diffuse distribution.	"Compatible with HP" patterns are nonspecific patterns that have been described in NFHP.	N/A
Relevant radiological findings	—HRCT abnormalities indicative of parenchymal infiltration: ● GGO ● Mosaic attenuation* —HRCT abnormalities indicative of small airway disease: ● Ill-defined, centrilobular nodules ● Air trapping† —Distribution of parenchymal abnormalities: ● Craniocaudal: diffuse (with or without some basal sparing) ● Axial: diffuse	—Parenchymal abnormalities ● Uniform and subtle GGO ● Airspace consolidation ● Lung cysts —Distribution of parenchymal abnormalities: ● Craniocaudal: diffuse (variant: lower lobe predominance) ● Axial: diffuse (variant: peribronchovascular)	N/A
FHP pattern			
Description	"Typical HP" pattern is suggestive of a diagnosis of FHP. It requires *1*) HRCT pattern of lung fibrosis (as listed below) in one of the distributions and *2*) at least one abnormality that is indicative of small airway disease.	"Compatible with HP" patterns exist when HRCT pattern and/or distribution of lung fibrosis varies from that of typical HP pattern; the variant fibrosis should be accompanied by signs of small airway disease.	The "Indeterminate for HP" pattern exists when the HRCT is neither suggestive nor compatible with a typical and probable FHP pattern.
Relevant radiological findings	—HRCT abnormalities indicative of lung fibrosis are most commonly composed of irregular linear opacities/ coarse reticulation with lung distortion. Traction bronchiectasis and honeycombing may be present but do not predominate. —The distribution of fibrosis may be: ● Random both axially and craniocaudally, or ● Mid-lung zone predominant, or ● Relatively spared in the lower lung zones —HRCT abnormalities indicative of small airway disease: ● Ill-defined, centrilobular nodules and/or GGO ● Mosaic attenuation, three-density pattern‡, and/or air trapping *(often in a lobular distribution)*	—Variant patterns of lung fibrosis: ● UIP pattern: basal and subpleural distribution of honeycombing with/ without traction bronchiectasis (per 2018 Diagnosis of IPF guidelines) ● Extensive GGO with superimposed subtle features of lung fibrosis —Variant (predominant) distributions of lung fibrosis: ● Axial: peribronchovascular, subpleural areas ● Craniocaudal: upper lung zones —HRCT abnormalities indicative of small airway disease: ● Ill-defined centrilobular nodules, or ● Three-density pattern‡ and/or air trapping	—Lone patterns (i.e., not accompanied by other findings suggestive of HP) of: ● UIP pattern (as per 2018 IPF diagnosis guidelines) ● Probable UIP pattern (as per 2018 IPF diagnosis guidelines) ● Indeterminate pattern for UIP (as per 2018 IPF diagnosis guidelines) ● Fibrotic NSIP pattern ● OP-like pattern ● Truly indeterminate HRCT pattern

Definition of abbreviations: FHP = fibrotic hypersensitivity pneumonitis; GGO = ground-glass opacities; HP = hypersensitivity pneumonitis; HRCT = high-resolution computed tomographic; IPF = idiopathic pulmonary fibrosis; N/A = not applicable; NFHP = nonfibrotic hypersensitivity pneumonitis; NSIP = nonspecific interstitial pneumonitis; OP = organizing pneumonia; UIP = usual interstitial pneumonitis.
Rarely, FHP may be seen *1*) as a component of combined pulmonary fibrosis and emphysema or pleuroparenchymal fibroelastosis with emphysema, *2*) as a pure emphysematous form of HP, or *3*) in acute exacerbation. Adapted by permission from Reference 2.
*Mosaic attenuation corresponding to parenchymal infiltration is created by GGO adjacent to normal-appearing lung.
†Air trapping appears as focal areas of hypoattenuation in background of hyperattenuating normal lung on expiratory images.
‡The three-density pattern was formerly called the "headcheese sign."

centriacinar fibrosis. Histopathological features of NFHP and FHP are categorized as *HP*, *Probable HP*, and *Indeterminate for HP*. For histopathological diagnostic confidence, the following must be absent in any biopsy site: A) plasma cells > lymphocytes, B) extensive lymphoid hyperplasia, C) extensive well-formed sarcoidal and/or necrotizing granulomas, and D) aspirated particles. Such features suggest an alternative diagnosis. Qualitatively, granulomas in HP are distinguished as small and poorly formed, with multinucleated giant cells in the peribronchiolar interstitium.

Histopathologic diagnosis of NFHP requires *1*) cellular interstitial pneumonia accentuated around small airways (bronchiolocentric), *2*) cellular bronchiolitis, *3*) poorly formed nonnecrotizing granulomas, *and 4*) lack of features suggesting an alternative

diagnosis (A–D above). *Probable NFHP* requires lymphocyte-rich, bronchiolocentric interstitial pneumonia and associated bronchiolitis in the absence of granulomatous inflammation. *Indeterminate NFHP* lacks granulomatous inflammation and features cellular bronchiolocentric interstitial pneumonia or unexplained cellular bronchiolitis.

Distinguishing FHP from other fibrotic idiopathic interstitial pneumonias often requires biopsy sampling from more than one site, similar to IPF, in which diagnostic discordance between sites is not uncommon (15). For FHP, typical histopathological features include chronic fibrosing interstitial pneumonia or airway centered fibrosis and poorly formed nonnecrotizing granulomas without features in any biopsy site to suggest alternative diagnosis (A–D above). Features of *Probable FHP* are similar to FHP but lack granulomas. *Indeterminate for FHP* criteria consist of chronic fibrosing interstitial pneumonia and absence of features to suggest alternate diagnosis. FHP may have overlap with features of UIP and fibrotic NSIP. Differentiating FHP from other fibrotic idiopathic interstitial pneumonias relies on identification of centriacinar fibrotic lesions and features of NFHP. Airway-centered fibrosis and peribronchiolar metaplasia are generally more pronounced in HP than other fibrotic lung diseases (16).

Diagnostic Criteria

No individual feature on history, HRCT imaging, or histopathology is adequate in isolation or mandatory to make a diagnosis of HP. Diagnosis is ideally made via multidisciplinary discussion (MDD). Identifying a culprit exposure is not essential to diagnosis; up to 50% of patients with FHP do not have an identifiable exposure even when evaluated at an ILD center (6).

Patients with NFHP often have onset of pulmonary and systemic symptoms temporally related to an acute and identifiable exposure with centrilobular nodularity seen on HRCT imaging and BAL lymphocytosis. In contrast, patients with FHP are less likely to have an identifiable antigen exposure and more likely to have insidious onset of pulmonary symptoms over time and a nonspecific BAL cell differential with fibrotic changes on HRCT.

The guideline proposes a new diagnostic algorithm for NFHP and FHP (Figure 1). Three domains are emphasized: *1*) exposure identification (clinical history, antigen-specific serum IgG, and/or specific

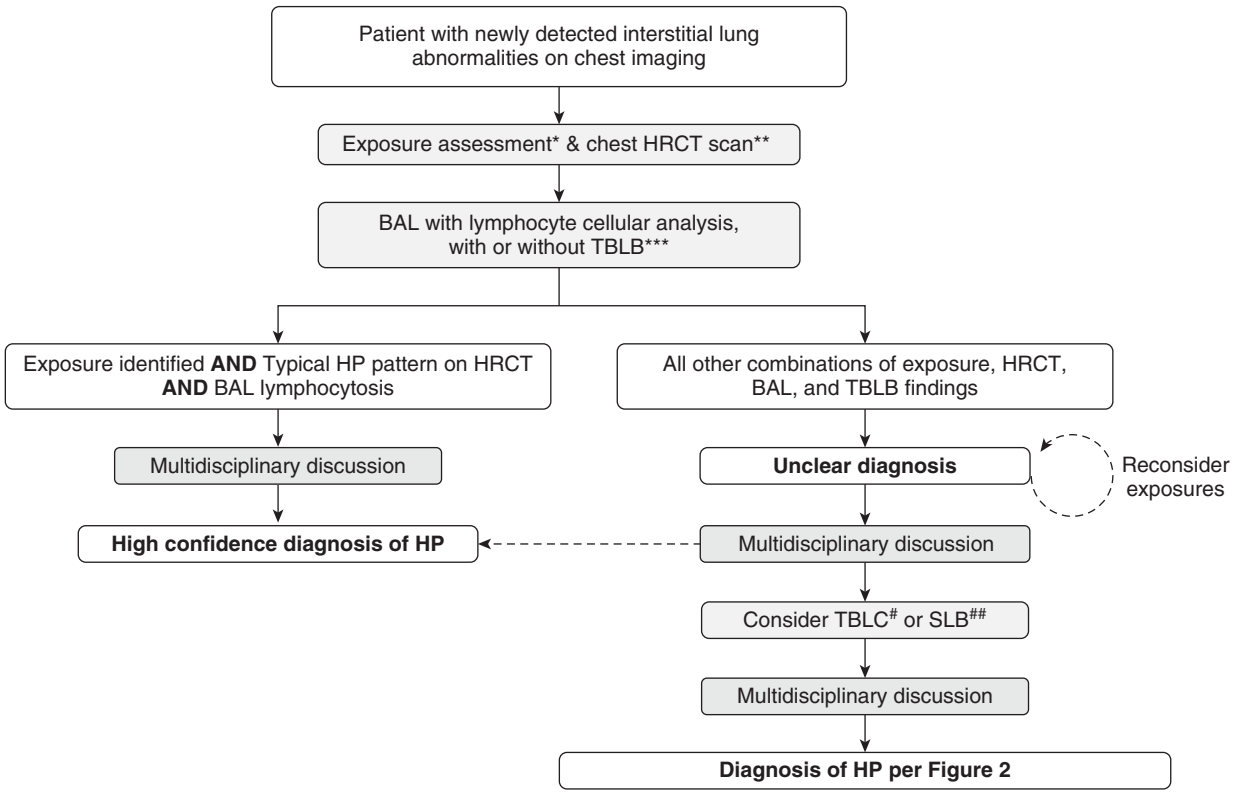

Figure 1. Algorithm for diagnostic evaluation of suspected HP. *Exposure assessment includes a thorough clinical history and/or serum IgG testing against potential antigens associated with HP and/or, in centers with the appropriate expertise and experience, specific inhalational challenge testing. **HRCT imaging should be performed using the technique described in Reference 2 and then reviewed with a thoracic radiologist. ***Transbronchial lung biopsy is suggested for patients with potential nonfibrotic HP (*see* question 4, recommendation 1). #TBLC is suggested for patients with potential nonfibrotic HP, depending on local expertise (*see* question 5, recommendation 2). ##SLB is infrequently considered in patients with nonfibrotic HP. Adapted by permission from Reference 2. BAL = bronchoalveolar lavage; HP = hypersensitivity pneumonitis; HRCT = high-resolution computed tomographic; IgG = immunoglobulin G; SLB = surgical lung biopsy; TBLB = transbronchial lung biopsy; TBLC = transbronchial lung cryobiopsy.

inhalational challenge); *2*) imaging pattern; and *3*) BAL lymphocytosis and/or histopathologic findings. Multiple combinations of abnormalities can result in HP diagnosis (Figure 2). The level of diagnostic confidence follows an approach proposed for fibrotic ILDs: definite (⩾90% confidence), high confidence (80–89%), moderate confidence (70–79%), and low confidence (<69%) (17). HP diagnosis of the highest confidence can be made in patients with a culprit exposure, *Typical HP* HRCT pattern, and BAL lymphocytosis without invasive testing. For all other patients, MDD with or without subsequent histopathological sampling is recommended to achieve an acceptable level of diagnostic confidence.

In the absence of exposure history and the presence of HRCT image pattern *Indeterminate for HP* with histopathology typical for HP, the confidence level of the diagnosis of HP may be increased to "definite" if the pathologist's conclusion of *Typical HP* persists after reevaluation in the context of additional clinical information or an expert second opinion on histopathology (Figure 2).

Diagnostic Interventions

The panel addressed six specific questions to provide recommendations for diagnostic interventions (Table 3).

Questionnaires

For patients with newly detected ILD whose differential diagnosis includes HP, the panel made no recommendation or suggestion regarding the use of a specific questionnaire to identify potential inciting antigens of HP (very low quality of evidence).

The panel based its decision on a lack of available evidence but agreed as to the potential role of a questionnaire as part of the diagnostic pathway. Future research should focus on the development and validation of a comprehensive questionnaire. In the interim, a thorough history is recommended to identify potential causative antigens (2, 18).

Serum IgG Testing

For patients with newly detected ILD whose differential diagnosis includes NFHP or FHP, the panel suggested performing serum IgG testing that targets potential antigens associated with HP (very low quality of evidence).

Most of the panel agreed that serum IgG testing was convenient and generated adequate supportive data for HP diagnosis, but alone would be insufficient to confirm or exclude HP diagnosis. The panel acknowledged the lack of standardization for serum IgG testing worldwide and suggested development and validation of a standardized hypersensitivity panel (2, 18).

BAL Fluid Lymphocyte Cellular Analysis

For patients with newly detected ILD whose differential diagnosis includes NFHP, the panel recommended BAL with lymphocyte cellular analysis (strong recommendation, very low quality of evidence). For patients with newly detected ILD whose differential diagnosis includes FHP, the panel suggested performing BAL with lymphocyte cellular analysis (very low quality of evidence).

Based on the available evidence, most of the panel felt that BAL fluid cellular lymphocyte analysis can be key in distinguishing NFHP from sarcoidosis and FHP from IPF and sarcoidosis. The panel could not identify a threshold

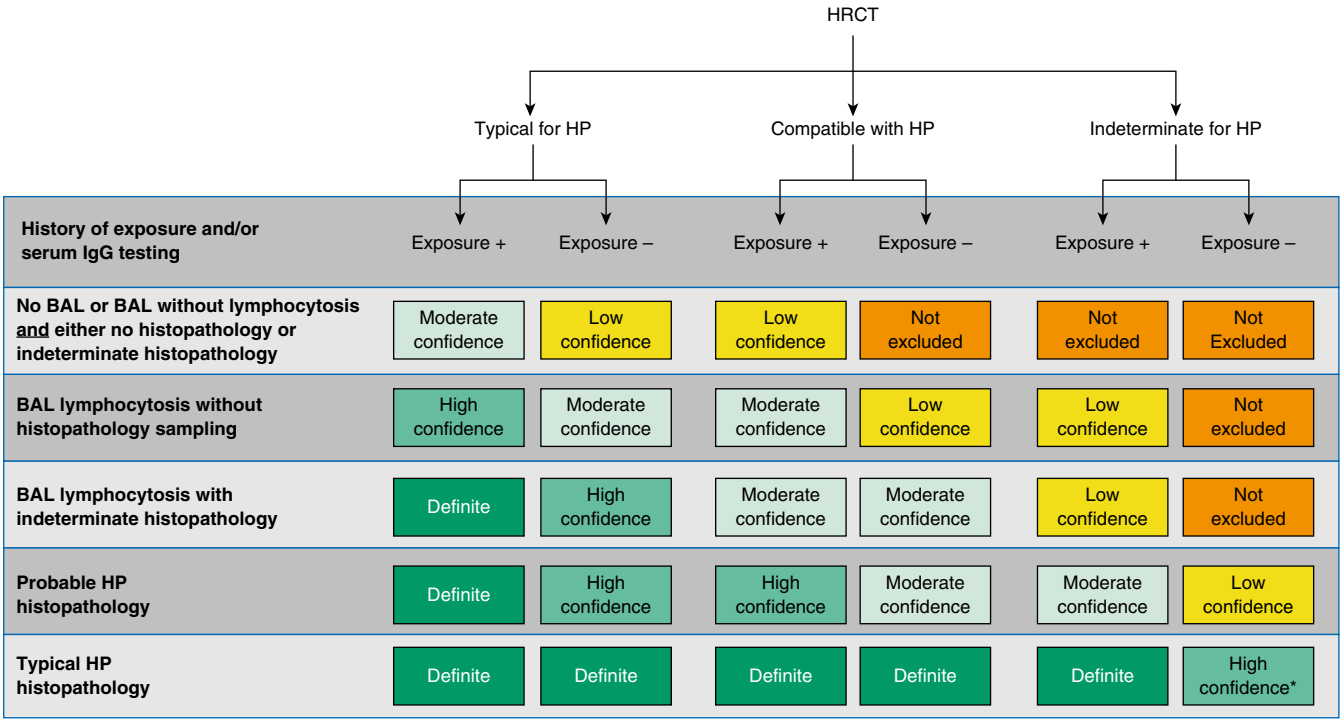

Figure 2. HP diagnostic approach. All confidence levels are subject to multidisciplinary discussion. *Confidence may increase to "definite" if the pathologist's conclusion persists after reevaluation in the context of additional clinical information or an expert second opinion on histopathology. Reprinted by permission from Reference 2. BAL = bronchoalveolar lavage; HP = hypersensitivity pneumonitis; HRCT = high-resolution computed tomographic; IgG = immunoglobulin G.

BAL lymphocytosis that would provide confidence in distinguishing HP from ILDs. Pooled data using a threshold of 20% showed that mean BAL fluid lymphocyte count is higher in HP (particularly NFHP) than in sarcoidosis and IPF, with sensitivity decreasing and specificity increasing with higher thresholds (i.e., 30% and 40%). The collective expertise of the panel suggested that a 30% threshold would be reasonable (19). The panel made a stronger recommendation for BAL in patients with suspected NFHP owing to the need to exclude pulmonary infection (2, 20).

Transbronchial Forceps Lung Biopsy

For patients with newly detected ILD whose differential diagnosis includes NFHP, the panel suggested performing transbronchial forceps lung biopsy (TBBx) (very low quality of evidence). For patients with newly detected ILD whose differential diagnosis includes FHP, the panel made no recommendation or suggestion regarding TBBx (very low quality of evidence).

The panel agreed that diagnostic yield (number of procedures yielding a histopathological diagnosis out of total

Table 3. Questions and recommendations from the 2020 hypersensitivity pneumonitis clinical practice guideline panel

Question	Recommendation
Q1. Should patients with newly detected ILD in chest radiographs or a CT scan of the chest, with or without an overt history of exposures capable of causing ILD in the patient's environment at home, work, or elsewhere, be subjected to formal questioning using a questionnaire to raise the possibility that *1*) potential inciting agent/s of HP are the etiology of the ILD and *2*) the diagnosis of the ILD is HP?	For patients with newly detected ILD whose differential diagnosis includes fibrotic or nonfibrotic HP, the panel makes no recommendation or suggestion for or against the use of a specific questionnaire to identify potential inciting agents of HP (*very low quality of evidence*). The panel recommends the development and validation of a questionnaire.
Q2. Should patients with newly detected ILD in chest radiographs or a CT scan of the chest, with or without an overt history of exposures capable of causing ILD in the patient's environment at home, work, or elsewhere, undergo serum testing for IgG antibodies against specific antigens to raise the possibility that *1*) potential inciting agent/s of HP are the etiology of the ILD and *2*) the diagnosis of the ILD is HP?	For patients with newly detected ILD whose differential diagnosis includes fibrotic or nonfibrotic HP, the panel suggests performing serum IgG testing that targets potential antigens associated with HP (*very low quality of evidence*).
Q3. Should patients with newly detected ILD in chest radiographs or a CT scan of the chest, with or without a history of exposure capable of causing HP, undergo bronchoalveolar lavage fluid lymphocyte cellular analysis to diagnose HP?	For patients with newly detected ILD whose differential diagnosis includes nonfibrotic HP, the panel recommends bronchoalveolar lavage with lymphocyte cellular analysis (*very low quality of evidence*). For patients with newly detected ILD whose differential diagnosis includes fibrotic HP, the panel suggests performing bronchoalveolar lavage with lymphocyte cellular analysis (*very low quality of evidence*).
Q4. Should patients with newly detected ILD in chest radiographs or a CT scan of the chest, with or without a history of exposure capable of causing HP, undergo transbronchial forceps lung biopsy to diagnose HP?	For patients with newly detected ILD whose differential diagnosis includes nonfibrotic HP, the panel suggests performing transbronchial forceps lung biopsy (*very low quality of evidence*). For patients with newly detected ILD whose differential diagnosis includes fibrotic HP, the panel makes no recommendation or suggestion for or against performing transbronchial forceps lung biopsy (*very low quality of evidence*).
Q5. Should patients with newly detected ILD in chest radiographs or a CT scan of the chest, with or without a history of exposure capable of causing HP, undergo transbronchial lung cryobiopsy to diagnose HP?	For patients with newly detected ILD whose differential diagnosis includes nonfibrotic HP, the panel makes no recommendation or suggestion for or against performing transbronchial cryobiopsy (*very low quality of evidence*). For patients with newly detected ILD whose differential diagnosis includes fibrotic HP, the panel suggests performing transbronchial cryobiopsy (*very low quality of evidence*).
Q6. Should patients with newly detected ILD in chest radiographs or CT scan chest, with or without a history of exposure capable of causing HP, undergo surgical lung biopsy to diagnose HP?	For patients with newly detected ILD whose differential diagnosis includes fibrotic or nonfibrotic HP, the panel suggests performing surgical lung biopsy after alternative diagnostic options have been exhausted (*very low quality of evidence*).

Definition of abbreviations: CT = computed tomographic; HP = hypersensitivity pneumonitis; IgG = immunoglobulin G; ILD = interstitial lung disease.

procedures performed) of TBBx was suboptimal and could lead to diagnostic misclassification. Pooled data indicated that diagnostic yields were higher among patients with diffuse lung disease (DLD) (68%) than those with ILD (37%). Patients with DLD were more likely to receive a non-ILD diagnosis (i.e., malignancy or infection). This was extrapolated to suggest that diagnostic yield may be higher in suspected NFHP and supported the conditional recommendation for TBBx in suspected NFHP but not in suspected FHP. Complications with TBBx include pneumothorax (7%) and moderate to severe bleeding (4%) (2, 21).

Transbronchial Lung Cryobiopsy

For patients with newly detected ILD whose differential diagnosis includes NFHP, the panel made no recommendation or suggestion regarding transbronchial lung cryobiopsy (TBLC) (very low quality of evidence). For patients with newly detected ILD whose differential diagnosis includes FHP, the panel suggested performing TBLC (very low quality of evidence).

Pooled data showed that the diagnostic yields were 91%, 82%, and 82% among patients with known or suspected HP, ILD, and DLD, respectively. Patients with known or suspected HP (100%), ILD (7.2%), or DLD (13.4%) had HP confirmed when a diagnosis was made by TBLC. Complications with TBLC vary with population but include bleeding of any severity (4–11%) and pneumothorax (10–27%). The panel recommended TBLC for suspected FHP as it may lead to the avoidance of surgical lung biopsy (SLB). No recommendation was made regarding TBLC for patients with suspected NFHP; TBBX, which has fewer complications, was recommended for NFHP (2, 21).

Surgical Lung Biopsy

For patients with newly detected ILD whose differential diagnosis includes HP, the panel suggested performing SLB after alternative diagnostic options have been exhausted (very low quality of evidence).

Pooled data showed that diagnostic yields were 96%, 98%, and 96% among patients with known or suspected HP, ILD, and DLD, respectively. Patients with known or suspected HP (91%), ILD (9%), or DLD (9%) had HP confirmed when a diagnosis was made by SLB. Complications with SLB include persistent pneumothorax after chest tube removal (4%), prolonged air leak (3%), respiratory infection (3%), delayed wound healing (3%), procedural mortality (2%), postprocedural exacerbation or respiratory failure (2%), and bleeding (1%). The panel agreed that diagnostic yield by SLB was high with a low complication rate and suggested SLB should be used after comprehensive MDD when other diagnostic tests fail to result in a definitive diagnosis (2).

Future Directions

This guideline defines clinical manifestations, pathogenesis, and radiological and histopathological features of HP and proposes new diagnostic criteria and graded recommendations for the diagnostic approach. Further study of HP pathophysiology and natural history and evaluation of diagnostic and therapeutic approaches is crucial. Future research should aim to validate and standardize a questionnaire for clinical use, determine a BAL lymphocytosis threshold, identify specific HP antibodies, and explore biomarkers of disease. There is a need for clinical and translational research, including HP-specific registries, to explore management of HP by subtype. Updating of this guideline is warranted upon the availability of new evidence. ■

Author disclosures are available with the text of this article at www.atsjournals.org.

References

1 Lacasse Y, Selman M, Costabel U, Dalphin JC, Ando M, Morell F, *et al.*; HP Study Group. Clinical diagnosis of hypersensitivity pneumonitis. *Am J Respir Crit Care Med* 2003;168:952–958.

2 Raghu G, Remy-Jardin M, Ryerson CJ, Myers JL, Kreuter M, Vasakova M, *et al*. Diagnosis of hypersensitivity pneumonitis in adults: an official ATS/JRS/ALAT clinical practice guideline. *Am J Respir Crit Care Med* 2020;202:e36–e69.

3 Raghu G, Remy-Jardin M, Myers JL, Richeldi L, Ryerson CJ, Lederer DJ, *et al.*; American Thoracic Society, European Respiratory Society, Japanese Respiratory Society, and Latin American Thoracic Society. Diagnosis of idiopathic pulmonary fibrosis: an official ATS/ERS/JRS/ALAT clinical practice guideline. *Am J Respir Crit Care Med* 2018;198:e44–e68.

4 Salisbury ML, Gu T, Murray S, Gross BH, Chughtai A, Sayyouh M, *et al*. Hypersensitivity pneumonitis: radiologic phenotypes are associated with distinct survival time and pulmonary function trajectory. *Chest* 2019;155:699–711.

5 Walsh SL, Sverzellati N, Devaraj A, Wells AU, Hansell DM. Chronic hypersensitivity pneumonitis: high resolution computed tomography patterns and pulmonary function indices as prognostic determinants. *Eur Radiol* 2012;22:1672–1679.

6 Fernández Pérez ER, Swigris JJ, Forssén AV, Tourin O, Solomon JJ, Huie TJ, *et al*. Identifying an inciting antigen is associated with improved survival in patients with chronic hypersensitivity pneumonitis. *Chest* 2013;144:1644–1651.

7 Vourlekis JS, Schwarz MI, Cherniack RM, Curran-Everett D, Cool CD, Tuder RM, *et al*. The effect of pulmonary fibrosis on survival in patients with hypersensitivity pneumonitis. *Am J Med* 2004;116:662–668.

8 Fernández Pérez ER, Kong AM, Raimundo K, Koelsch TL, Kulkarni R, Cole AL. Epidemiology of hypersensitivity pneumonitis among an insured population in the United States: a claims-based cohort analysis. *Ann Am Thorac Soc* 2018;15:460–469.

9 De Sadeleer LJ, Hermans F, De Dycker E, Yserbyt J, Verschakelen JA, Verbeken EK, *et al*. Effects of corticosteroid treatment and antigen avoidance in a large hypersensitivity pneumonitis cohort: a single-centre cohort study. *J Clin Med* 2018;8:14.

10 Vasakova M, Selman M, Morell F, Sterclova M, Molina-Molina M, Raghu G. Hypersensitivity pneumonitis: current concepts of pathogenesis and potential targets for treatment. *Am J Respir Crit Care Med* 2019;200:301–308.

11 Ley B, Newton CA, Arnould I, Elicker BM, Henry TS, Vittinghoff E, *et al*. The MUC5B promoter polymorphism and telomere length in patients with chronic hypersensitivity pneumonitis: an observational cohort-control study. *Lancet Respir Med* 2017;5:639–647.

12 Newton CA, Batra K, Torrealba J, Kozlitina J, Glazer CS, Aravena C, *et al*. Telomere-related lung fibrosis is diagnostically heterogeneous but uniformly progressive. *Eur Respir J* 2016;48:1710–1720.

13 Okamoto T, Miyazaki Y, Tomita M, Tamaoka M, Inase N. A familial history of pulmonary fibrosis in patients with chronic hypersensitivity pneumonitis. *Respiration* 2013;85:384–390.

14 Barnett J, Molyneaux PL, Rawal B, Abdullah R, Hare SS, Vancheeswaran R, *et al*. Variable utility of mosaic attenuation to distinguish fibrotic hypersensitivity pneumonitis from idiopathic pulmonary fibrosis. *Eur Respir J* 2019;54:1900531.

15 Flaherty KR, Travis WD, Colby TV, Toews GB, Kazerooni EA, Gross BH, *et al*. Histopathologic variability in usual and nonspecific interstitial pneumonias. *Am J Respir Crit Care Med* 2001;164:1722–1727.

16 Akashi T, Takemura T, Ando N, Eishi Y, Kitagawa M, Takizawa T, *et al*. Histopathologic analysis of sixteen autopsy cases of chronic hypersensitivity pneumonitis and comparison with idiopathic pulmonary fibrosis/usual interstitial pneumonia. *Am J Clin Pathol* 2009;131:405–415.
17 Ryerson CJ, Corte TJ, Lee JS, Richeldi L, Walsh SLF, Myers JL, *et al*. A standardized diagnostic ontology for fibrotic interstitial lung disease: an international working group perspective. *Am J Respir Crit Care Med* 2017;196:1249–1254.
18 Jenkins AR, Chua A, Chami H, Diaz-Mendoza J, Duggal A, Knight S, *et al*. Questionnaires or serum immunoglobulin G testing in the diagnosis of hypersensitivity pneumonitis among patients with interstitial lung disease. *Ann Am Thorac Soc* 2021;18:130–147.
19 Meyer KC, Raghu G, Baughman RP, Brown KK, Costabel U, du Bois RM, *et al*.; American Thoracic Society Committee on BAL in Interstitial Lung Disease. An official American Thoracic Society clinical practice guideline: the clinical utility of bronchoalveolar lavage cellular analysis in interstitial lung disease. *Am J Respir Crit Care Med* 2012;185:1004–1014.
20 Patolia S, Tamae Kakazu M, Chami H, Chua A, Diaz-Mendoza J, Duggal A, *et al*. Bronchoalveolar lavage lymphocytes in the diagnosis of hypersensitivity pneumonitis among patients with interstitial lung disease: a systematic review. *Ann Am Thorac Soc* 2020;17:1455–1467.
21 Chami HA, Diaz-Mendoza J, Chua A, Duggal A, Jenkins AR, Knight SL, *et al*. Transbronchial biopsy and cryobiopsy in the diagnosis of hypersensitivity pneumonitis among patients with interstitial lung disease. *Ann Am Thorac Soc* 2021;18:148–161.